

American Journal of Sports Medicine

<http://ajs.sagepub.com>

The Active Compression Test: A New and Effective Test for Diagnosing Labral Tears and Acromioclavicular Joint Abnormality

Stephen J. O'Brien, Michael J. Pagnani, Stephen Fealy, Scott R. McGlynn and Joseph B. Wilson
Am. J. Sports Med. 1998; 26; 610

The online version of this article can be found at:
<http://ajs.sagepub.com/cgi/content/abstract/26/5/610>

Published by:

 SAGE Publications

<http://www.sagepublications.com>

On behalf of:



[American Orthopaedic Society for Sports Medicine](#)

Additional services and information for *American Journal of Sports Medicine* can be found at:

Email Alerts: <http://ajs.sagepub.com/cgi/alerts>

Subscriptions: <http://ajs.sagepub.com/subscriptions>

Reprints: <http://www.sagepub.com/journalsReprints.nav>

Permissions: <http://www.sagepub.com/journalsPermissions.nav>

Citations (this article cites 4 articles hosted on the
SAGE Journals Online and HighWire Press platforms):
<http://ajs.sagepub.com/cgi/content/abstract/26/5/610#BIBL>

The Active Compression Test: A New and Effective Test for Diagnosing Labral Tears and Acromioclavicular Joint Abnormality

Stephen J. O'Brien,* MD, Michael J. Pagnani, MD, Stephen Fealy, MD, Scott R. McGlynn, and Joseph B. Wilson

From the Department of Sports Medicine and Shoulder Service, The Hospital For Special Surgery, New York, New York

ABSTRACT

Labral tears and acromioclavicular joint abnormalities were differentiated on physical examination using a new diagnostic test. The standing patient forward flexed the arm to 90° with the elbow in full extension and then adducted the arm 10° to 15° medial to the sagittal plane of the body and internally rotated it so that the thumb pointed downward. The examiner, standing behind the patient, applied a uniform downward force to the arm. With the arm in the same position, the palm was then fully supinated and the maneuver was repeated. The test was considered positive if pain was elicited during the first maneuver, and was reduced or eliminated with the second. Pain localized to the acromioclavicular joint or "on top" was diagnostic of acromioclavicular joint abnormality, whereas pain or painful clicking described as "inside" the shoulder was considered indicative of labral abnormality. A prospective study was performed on 318 patients to determine the sensitivity, specificity, and positive and negative predictive values of the test. Fifty-three of 56 patients whose preoperative examinations indicated a labral tear had confirmed labral tears that were repaired at surgery. Fifty-five of 62 patients who had pain in the acromioclavicular joint and whose preoperative examinations indicated abnormalities in the joint had positive clinical, operative, or radiographic evidence of acromioclavicular injury. There were no false-negative results in either group.

The diagnosis and treatment of labral disorders of the shoulder are the subjects of significant controversy among orthopaedic surgeons.² Snyder et al.⁴ first described the SLAP (superior labral anterior and posterior) lesion and refocused our attention on the importance of the labrum in clinical disorders of the shoulder. Studies have also been completed at our institution that illustrate significant anatomic variations in the capsulolabral and bicipital-labral portions of the shoulder and the effect of the vascular anatomy on the ability to effect labral repair.^{1,3} The lack of a reliable test for superior labral tears has made accurate diagnosis of this entity difficult. Similarly, radiographic evaluation of labral abnormality has been slow to develop.

The senior author (SJO) developed a new diagnostic test for the clinical detection of labral abnormality that is also sensitive and specific for acromioclavicular joint abnormality. The test is based on the fact that both the clinician and patient can distinguish between pain "on top" of the shoulder (that is, at the acromioclavicular joint) and pain "deep inside" the shoulder joint with or without a click. We conducted a prospective study to evaluate this test for its efficacy.

MATERIALS AND METHODS

A prospective protocol was established to evaluate the sensitivity, specificity, and positive and negative predictive values of the new diagnostic test. This test was conducted with the physician standing behind the patient (Fig. 1). The patient was asked to forward flex the affected arm 90° with the elbow in full extension. The patient then adducted the arm 10° to 15° medial to the sagittal plane of the body. The arm was internally rotated so that the thumb pointed downward. The examiner then applied a uniform downward force to the arm. With the arm in the same position, the palm was then fully supinated and the maneuver was repeated. The test was considered positive

* Address correspondence and reprint requests to Stephen J. O'Brien, MD, Department of Sports Medicine and Shoulder Service, The Hospital for Special Surgery, 535 East 70th Street, New York, NY 10021.

No author or related institution has received any financial benefit from research in this study.

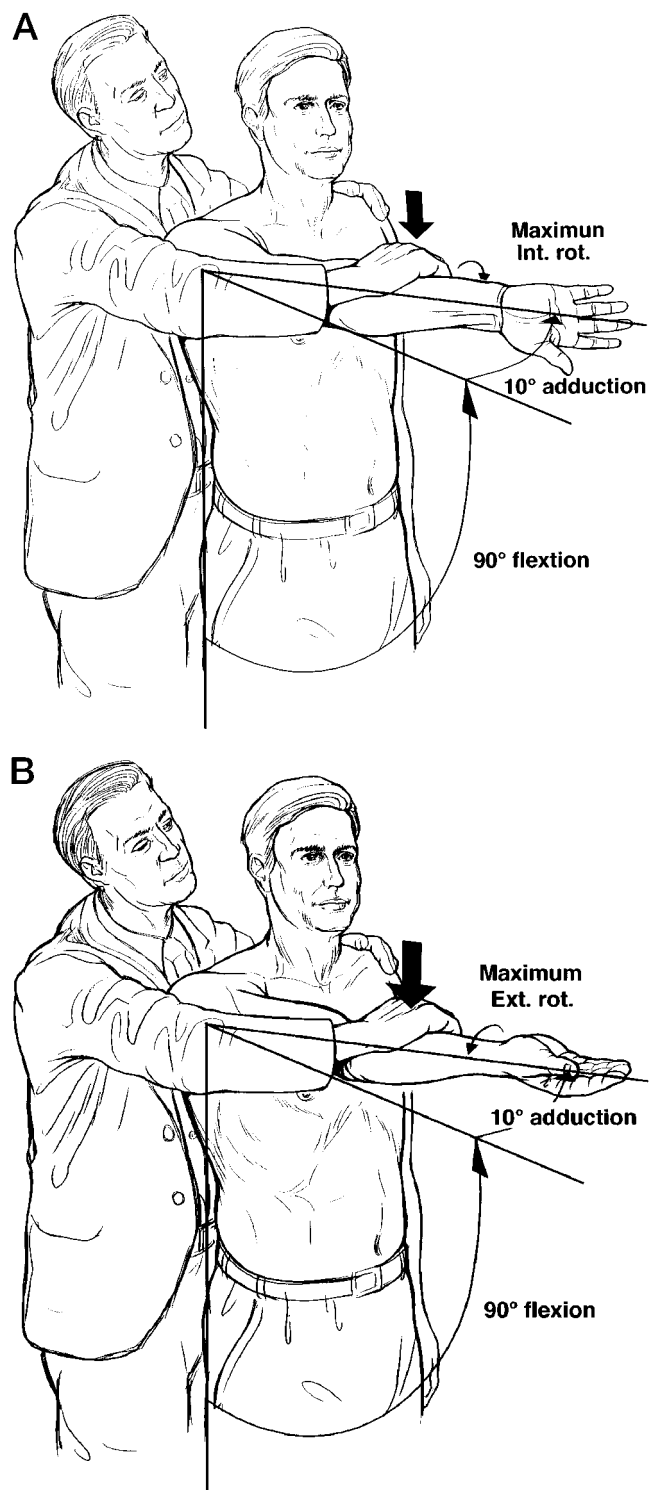


Figure 1. In the active compression test, the patient's arm is forward flexed to 90°, adducted 10° to 15°, and maximally internally rotated. The patient is instructed to resist as the examiner applies a uniform downward force (A). The patient then maximally supinates the arm and the maneuver is repeated (B).

if pain was elicited with the first maneuver and was reduced or eliminated with the second maneuver. Pain localized to the acromioclavicular joint or on top of the shoulder was diagnostic of acromioclavicular joint abnormality. Pain or painful clicking described as inside the glenohumeral joint itself was indicative of labral abnormality.

Three hundred eighteen patients were studied prospectively at our institution. At the time of physical examination, we performed an active compression test on 268 consecutive patients with shoulder pain who had had no prior diagnostic evaluation. The examinations were performed without the examiner knowing the results of radiographic examination of the shoulder. Fifty patients who had come to our institution with knee pain and who denied shoulder problems were used as controls. The maneuver was verified by various combinations of radiography, MRI, and clinical data. Fifty patients who had not had complete or properly performed examinations to support the accuracy of the test were not included in the study.

RESULTS

Fifty-six patients had positive active compression tests believed to reflect labral tears. Fifty-three of the 56 had confirmed labral tears at surgery. There were three false-positive results. One patient had a reverse Hill-Sachs lesion. One patient had a hypermobile biceps tendon with multidirectional laxity and biceps tendinitis. One patient had anterior instability without a discrete labral tear. There were no false-negative results in this group.

Sixty-two patients had positive active compression tests believed to reflect acromioclavicular joint abnormality. Fifty-five of these 62 patients had various combinations of radiographs, MRI scans, and surgical confirmation of acromioclavicular joint abnormality. Thirty-two patients had radiographic confirmation alone, and 23 patients had additional surgical confirmation. No patients who had surgical treatment of their acromioclavicular joint abnormalities had recurrences of their symptoms. No postoperative corticosteroid injections were administered, and all patients noted complete relief of their pain after surgery.

There were seven false-positive results in this group. Four patients had biceps tendinitis with MRI confirmation; two of these four also had multidirectional laxity. Two patients had dislocated biceps tendons confirmed by MRI. One patient who had pain at the sternoclavicular joint and acromioclavicular joint with the active compression test maneuver had a symptomatic sternoclavicular subluxation. This test was included as a false-positive test. There were no false-negative results in this group.

There were 150 patients with negative active compression tests who had other shoulder abnormalities confirmed by various combinations of radiographs, MRI, and surgery. Forty-eight patients had shoulder instability (42 anterior, 6 posterior). Fifty-four patients had confirmed rotator cuff tears, and 37 patients had confirmed impingement syndrome with evidence of a degenerative rotator

cuff or partial-thickness tear. Ten patients had biceps tendinitis and one patient had adhesive capsulitis.

Of the 56 patients undergoing surgery for suspected labral tears, 52 had preoperative MRI scans. The scans performed at our institution as well as outside studies were all read by our senior radiologist. Of the 52 MRI scans reviewed, our radiologist correctly diagnosed the presence or absence of labral tears, and also the location of the tears, in 44, for an accuracy rate of 84.6%.

Of the 50 patients who were used as controls, the dominant shoulder was examined. There were no positive tests in this group.

Data calculations for the accuracy of the active compression test regarding labral abnormality revealed a sensitivity of 100% (53 of 53), a specificity of 98.5% (200 of 203), a positive predictive value of 94.6% (53 of 56), and a negative predictive value of 100% (200 of 200). Calculations for accuracy of the active compression test for acromioclavicular joint abnormality were as follows: sensitivity, 100% (55 of 55); specificity, 96.6% (200 of 207); positive predictive value, 88.7% (55 of 62); negative predictive value, 100% (200 of 200).

Combined labral tears and acromioclavicular joint abnormality data (confirmed from above groups) yields a sensitivity of 100% (108 of 108), a specificity of 95.2% (200 of 210), a positive predictive value of 91.5% (108 of 118), and a negative predictive value of 100% (200 of 200).

DISCUSSION

The development of the active compression test began when a patient showed us what best reproduced his shoulder pain by using a maneuver that we had not used on routine physical examination. The patient had a degenerative acromioclavicular joint. After repeated confirmations of the ability of this maneuver to reproduce other patients' shoulder pain, we did a preliminary study look-

ing at the active compression test and found that the test was also excellent for determining labral abnormality.

Cadaveric studies were performed to examine the anatomic basis of the active compression test. Selective cutting was performed to create acromioclavicular joint instability after testing in the intact situation (Fig. 2A). Load at the acromioclavicular joint was crudely measured with a "paper pull out test" (that is, our ability to withdraw a sheet of paper placed in the acromioclavicular joint with different positions of the arm simulating the active compression test maneuver). In the unstable acromioclavicular joint (that is, after cutting the acromioclavicular capsule and coracoclavicular ligaments), there was no question that the highest pressure generated in the joint was with the arm forward flexed 90° with approximately 10° to 15° of adduction and maximal internal rotation (Fig. 2B). In this position the greater tuberosity elevates the relatively depressed acromion and "locks and loads" the acromioclavicular joint (Fig. 2C). Full supination relaxed the joint by virtue of the greater tuberosity moving out of the way. Maneuvers that moved the arm beyond 15° of adduction created a "bayonetting" effect, in which the override left the distal clavicle and medial portion of the acromion exposed and free of pressure other than tension of the overlying muscle. This may be why the adduction test that we performed for the acromioclavicular joint yielded such variable and often nonspecific results.

Abduction of the arm away from the midline also tended to relax the acromioclavicular joint. The test was further enhanced by the active muscular action of the deltoid coming from both the clavicle and acromion, creating further load at the acromioclavicular joint. The combination of positioning and deltoid muscular action would lock and load an incongruous or degenerative acromioclavicular joint, reproducing pain.

The mechanism by which the active compression test reproduced abnormal labral dynamics was quite different.

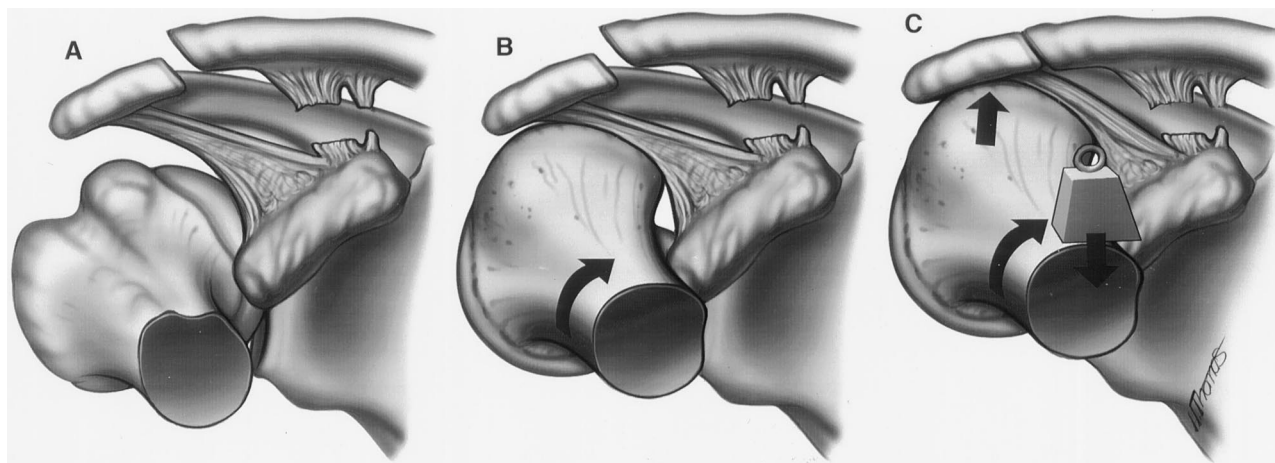


Figure 2. A, to demonstrate the anatomic basis of the active compression test, selective cutting was performed to create acromioclavicular joint instability after testing in the intact situation. B, in the unstable acromioclavicular joint the highest pressure generated was with the arm forward flexed 90° with approximately 10° to 15° of adduction and maximal internal rotation. C, in this position the greater tuberosity comes over and, by positioning, elevates the relatively depressed acromion and "locks and loads" the acromioclavicular joint.

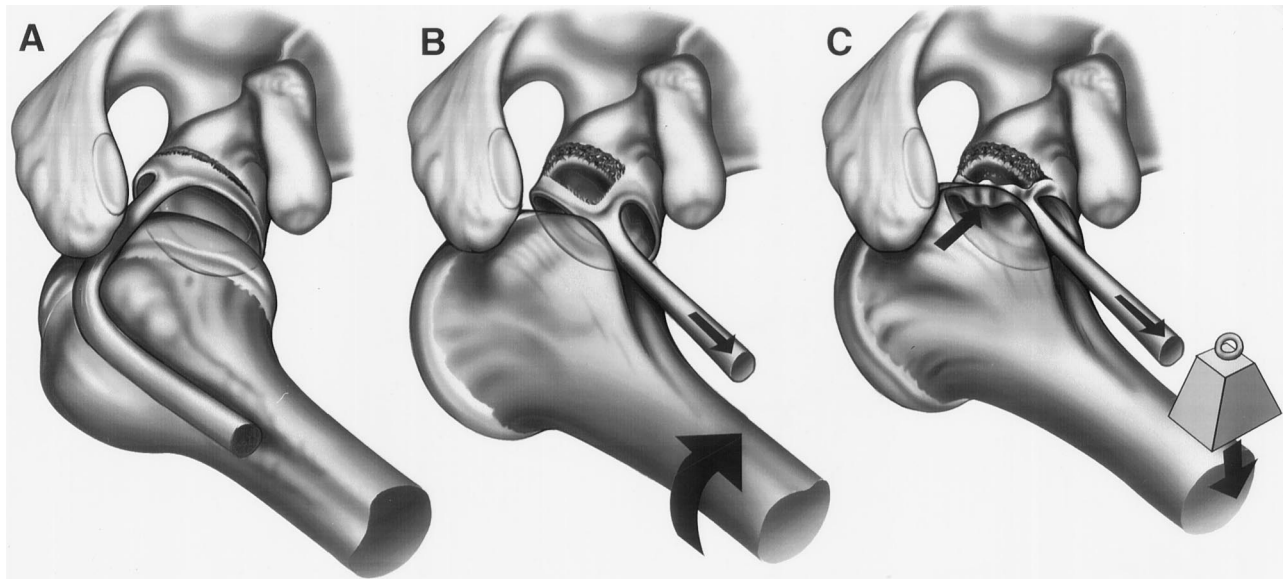


Figure 3. A, an anatomic drawing of the shoulder in neutral position without force applied. B, when the arm is positioned in 90° of forward flexion, 10° to 15° of adduction, and maximum internal rotation, the biceps tendon displaces medially and inferiorly, putting tension on the bicipital-labral complex. C, joint load increases because of the windup effect of the capsuloligament and musculotendon units.

We arthroscopically re-created the active compression test to observe the mechanical action of the abnormal labrum (Fig. 3A). When the arm is positioned in 90° of forward flexion, 10° to 15° of adduction, and maximum internal rotation, the biceps tendon displaces medially and inferiorly, thereby tensioning the bicipital-labral complex (Fig. 3B). This may secondarily create shear forces in the glenoid and labrum. In cases of displaceable labral tears (or unstable biceps tendons), the tension from the biceps tendon from shear, compression from the capsular “windup,” or both, will create an internal mechanical derangement and displacement that may account for the painful clicking that patients experience (Fig. 3C). We have been able to demonstrate on a number of occasions the displaceable labrum entering into, and being compressed in, the glenohumeral joint space.

There are some important considerations to keep in mind to perform the active compression test correctly. First and foremost, the arm must be in 90° of forward flexion, 15° of adduction, and maximum internal rotation. This will avoid confusion with other clinical tests commonly used. Second, for maximal results, the patient should be resisting the examiner’s downward force, not the examiner resisting the patient’s attempts to actively forward flex past 90°. Third, a test was considered positive only if the pain was reduced or eliminated with repeating the maneuver in 90° of forward flexion, 10° to 15° of adduction, and maximum supination. This avoided confusion in patients in which every shoulder movement hurt.

A natural sequela of our findings is that the active compression test should revert to negative when the labral or acromioclavicular joint abnormality is corrected. Although this was not done as part of this study, we are currently doing follow-up studies that show that the active

compression test is negative with correction of labral and acromioclavicular joint abnormality, demonstrating that it is an excellent way of following a patient’s progress. We use this test routinely now as part of any shoulder examination.

CONCLUSION

The active compression test is an effective test for labral abnormality, and one that is also sensitive and specific for acromioclavicular joint abnormality. Armed with this clinical tool, one can gain more perspective regarding the natural history of labral disorders. It also has become a valuable postoperative tool for monitoring the results of acromioclavicular joint and labral disorders.

ACKNOWLEDGMENTS

The authors thank Dr. Hollis Potter from the Department of Radiology for her time and effort with this project.

REFERENCES

1. Cooper DE, Arnoczky SP, O'Brien SJ, et al: Anatomy, histology and vascularity of the glenoid labrum. An anatomical study. *J Bone Joint Surg* 74A: 46–52, 1992
2. Liu SH, Henry MH, Nuccion SL: A prospective evaluation of a new physical examination in predicting glenoid labral tears. *Am J Sports Med* 24: 721–725, 1996
3. O'Brien SJ, Neves MC, Arnoczky SP, et al: The anatomy and histology of the inferior glenohumeral ligament complex of the shoulder. *Am J Sports Med* 18: 449–456, 1990
4. Snyder SJ, Karzel RP, Del Pizzo W, et al: SLAP lesions of the shoulder. *Arthroscopy* 6: 274–279, 1990